



Short Communication

Dementia from the ABCD1 mutation c.1415-1416delAG in a female carrier

Josef Finsterer^{a,*}, Stefan Lässer^b, Elisabeth Stöphasius^c^a Krankenanstalt Rudolfstiftung, Vienna, Austria^b 1st Medical Dpt., Krankenanstalt Rudolfstiftung, Vienna, Austria^c Radiology Dpt., Krankenanstalt Rudolfstiftung, Vienna, Austria

ARTICLE INFO

Article history:

Accepted 18 July 2013

Available online 18 August 2013

Keywords:

Adrenoleukodystrophy

Carrier

X-linked

Genetics

ABCD1 gene

ABSTRACT

Objectives: Progressive dementia is a rare phenotypic feature of female X-ALD carriers. Even rarer is the additional presence of further risk factors for dementia, such as diabetes, hypothyroidism, and hepatopathy. We report a unique female X-ALD carrier presenting with severe, progressive dementia, paraspasticity, sphincteric dysfunction, and multisystem disease.

Case report: A 79 years-old female with a history of strumectomy, diabetes, hepatopathy, hypothyroidism, arterial hypertension, hiatal hernia, left retinal ablation, ovariectomy, hysterectomy, osteoporosis, bilateral hip endoprosthesis, and neurogenic bladder dysfunction developed slowly progressive cognitive decline since age of 77 years. She had been identified as a female carrier of X-ALD in 12/2010 upon a family screening. At age of 79 years she presented with severe dementia, anxiety, unsteadiness, helplessness, hypertelorism, exaggerated patella tendon reflexes, reduced Achilles tendon reflexes, club feet, contractures of the ankles, the knees, and the hips, and the inability to stay or walk. Cerebral CT showed diffuse atrophy, demyelination periventricularly, small lacunas in the basal ganglia, and small calcifications of the basal ganglia and the temporal lobe on the right side. Differential diagnoses of dementia were considered but were all excluded upon the clinical presentation, blood chemical investigations, imaging studies, and the pattern of neuropsychological deficits.

Conclusions: With progression of the disease manifesting X-ALD carriers may develop progressive severe dementia, severe paraspasticity, and sphincteric dysfunction. Female carriership of X-ALD can be a differential diagnosis of dementia.

© 2013 Elsevier B.V. All rights reserved.

1. Introduction

X-linked adrenoleukodystrophy (X-ALD) is a serious and often fatal disorder of the white matter and the most frequent type of leukodystrophy (1/17000 males) (Boehm et al., 1999; Lesca et al., 2005). More than half (at least 20–50%) of the X-ALD female carriers display symptoms of the disease above age of 40 years (van Geel, 2000). However, cerebral manifestations, including progressive dementia, are rare. Even rarer is the additional presence of further risk factors for dementia, such as diabetes, hypothyroidism, and hepatopathy. The following case describes a unique female carrier of X-ALD presenting with severe, progressive dementia, paraspasticity, sphincter dysfunction, and multisystem disease.

1.1. Case report

The patient is a 79 year-old female, height of 165 cm, weight of 68 kg, with a history of partial strumectomy in 1990, diabetes since the past 20 years (insulin since 4 years), hepatopathy since at least the past 10 years, hypothyroidism, arterial hypertension, hiatal hernia, left retinal ablation, ovariectomy, hysterectomy, osteoporosis, bilateral hip endoprosthesis, and neurogenic bladder dysfunction, for which she had received a permanent urinary catheter since 1/2009. In 12/2010 she was identified as a female carrier of X-ALD after one of her two sons had been diagnosed with X-ALD and a family screening had been carried out (Brownstone et al., 2013). Like her severely affected son, she carried the mutation c.1415-1416delAG in the ABCD1 gene on Xq28 in the heterozygous form. Clinical neurologic examination in 4/2011 revealed severe dementia allowing her to follow hardly any task, perseveration of simple sentences and words, anxiety, unsteadiness, helplessness, hypertelorism, exaggerated patella tendon reflexes, reduced Achilles tendon reflexes, club feet, and contractures of the ankles, knees, and hips. She was unable to stand or walk. According to her son, dementia had started 2 years earlier and showed continuous progression since then. Blood chemical investigations in the fasting stage are

Abbreviations: CBD, cortico-basal degeneration; CNS, central nervous system; CT, computed tomography; LBD, Lewy-body dementia; MID, mitochondrial disorder; MRI, magnetic resonance imaging; MSA, multisystem atrophy; PSP, progressive supranuclear palsy; SDAT, Alzheimer's disease; VLCFA, very-long chain fatty acids; X-ALD, X-linked adrenoleukodystrophy.

* Corresponding author at: Postfach 20, 1180 Vienna, Austria. Tel.: +43 1 71165 92085; fax: +43 1 4781711.

E-mail address: fifigs1@yahoo.de (J. Finsterer).

Table 1
Blood chemical values during the last years in the presented patient.

Parameter	RL	3.10.03	29.12.06	17.12.12	17.4.13	19.4.13	21.4.13	23.4.13
Leuco	4–9G/l	7.44	10.6*	7.6	16.1*	11.7*	10.3*	9.3*
Ery	4–5.2 T/l	4.4	4.67	4.16	3.84*	3.47*	4.23	4.59
Hb	12–16 g/dl	12.7	14	10.1*	8.9*	8.2*	10.8*	11.6*
Hc	38–48%	38.4	41.4	32.5*	28*	25.6*	33.2*	35.5*
CRP	0–5 mg/l	0.11	6.8*	2.0*	277.3*	125.1*	60.3*	53.9*
Crea	0.5–1 mg/dl	0.76	0.74	0.85	4.44*	0.77	0.66	0.61
GFR	>90 ml/min	nd	nd	64*	10*	72*	87*	94
Glucose	82–115 mg/dl	217*	209*	429*	194*	nd	nd	nd
HbA1c	0–6.0%	7.6*	8.2*	11.4*	nd	7.2	nd	nd

RL: reference limits, Leuco: leucocytes, Ery: erythrocytes, Hb: hemoglobin, Hc: hematocrit, CRP: C-reactive protein, Crea: creatinine, GFR: glomerular filtration rate, nd: not determined.

* Abnormal value, blood chemistry was taken in a fasting stage each time.

presented in Table 1. There was anemia, elevation of liver function parameters, elevation of fasting glucose values, and the HbA1c was between 7.2 and 11.4% (n, 0–6%). Cerebral CT in 2013 showed diffuse atrophy, reduced density throughout the white matter, demyelination periventricularly, small lacunas in the basal ganglia, small calcifications of the basal ganglia and the temporal lobe on the right side, and calcifications of the falx (Fig. 1). Cerebral MRI was tried but had to be aborted because of the patient's agitation. Ultrasonography of the abdomen revealed a kidney cyst on the left side. Cerebral CT in 2003 showed right-sided basal ganglia calcification exclusively.

2. Discussion

Manifesting female X-ALD carriers have been previously reported (Jangouk et al., 2012; Krenn et al., 2001; Lesca et al., 2005; Matsumuro et al., 1991; Powers et al., 1987; Restuccia et al., 1997; Salsano et al., 2012; Schlote et al., 1987; Simpson et al., 1987). The estimated frequency of female X-ALD carriers is 1:14000 (Bezman et al., 2001). Typical phenotypic manifestations in X-ALD carriers include progressive spastic gait, sensory deficits, and bladder dysfunctions (Krenn et al., 2001). In a study of 19 female carriers mild abnormalities were found in two of the carriers upon clinical neurologic examination (Salsano et al., 2012). Cerebral MRI in 17 of them revealed various degrees of abnormalities, in one asymptomatic and in 5 symptomatic carriers (Salsano et al., 2012). Involvement of the central nervous system (CNS) was further established upon abnormal sensory-evoked potentials in 12 and

abnormal motor-evoked potentials in 8 patients (Salsano et al., 2012). Symptomatic carriers presented with severe neuropsychological deficits. The authors concluded that CNS involvement occurs in the majority of the female X-ALD carriers with onset at a preclinical stage and being severely progressive (Salsano et al., 2012). Another 40 year-old manifesting X-ALD carrier presented with spastic paraparesis, sphincteric dysfunction, and elevated very-long chain fatty acids (VLCFA) but without CNS involvement at the time of the investigation (Lesca et al., 2005). In a further 40 year-old female X-ALD carrier the underlying genetic defect manifested as spastic paraparesis of the lower legs, marked sensory deficits, visual disturbances, and bladder dysfunction (Restuccia et al., 1997). In a black African female, X-ALD carriership manifested with disorientation, concentration fatigue, getting lost easily, mild generalized weakness, quadraparesis, poor coordination, and hemianopsia (Krenn et al., 2001). Another manifesting female carrier of X-ALD manifested with seizures, stupor, and dementia (Schlote et al., 1987). Autopsy of this patient showed widespread demyelination of the cerebral white matter (Schlote et al., 1987). Biochemical studies revealed marked increase of VLCFA, particularly C26:0 in cholesterol esters and C24:0 and C24:1 in gangliosides (Schlote et al., 1987). Neurological abnormalities in female X-ALD carriers were also reported by others (Powers et al., 1987). A further female carrier manifested with episodes of impaired consciousness, positive pyramidal signs, cerebral demyelination, and bilateral basal ganglia calcifications (Matsumuro et al., 1991). Dementia was particularly reported in the patients described by (Matsumuro et al., 1991; Salsano et al., 2012; Schlote et al., 1987). It appears that dementia develops with progression of the disease. Generally, cerebral involvement, including progressive dementia, is estimated to occur with a frequency of 2% among female X-ALD carriers (Moser et al., 2004).

Concerning the imaging findings in female X-ALD carriers, they are non-specific. Imaging findings of the present case are consistent with findings from previous studies (Matsumuro et al., 1991; Restuccia et al., 1997; Salsano et al., 2012). However, some studies also described features in X-ALD carriers, which are typically found in multiple sclerosis (Krenn et al., 2001). In these cases cerebral MRI may show multiple peri-ventricular white matter lesions, which are sometimes enhancing and similar in shape and distribution to those seen in multiple sclerosis (Restuccia et al., 1997). Though most imaging features of the cerebrum in X-ALD carriers are consistent between patients, imaging abnormalities in X-ALD carriers are generally non-specific and justify a screening for X-ALD carrier status only if the family history is positive for the disease or if long-chain fatty acids are elevated. Identification of X-ALD carriers by means of VLCFA assays results in 5–10% false negatives (Inoue et al., 1996), why it is unreliable to exclude the carrier status biochemically alone (Boehm et al., 1999).

Differential diagnoses of dementia in the presented patient, like vascular dementia or neurodegenerative dementias, such as tauopathies, Parkinson disease, prion diseases, or Huntington's disease, were excluded upon the clinical presentation, the disease course, and the imaging findings. Our patient had no history of stroke embolism, or transitory ischemic attack, no features of Parkinson's disease, multisystem atrophy

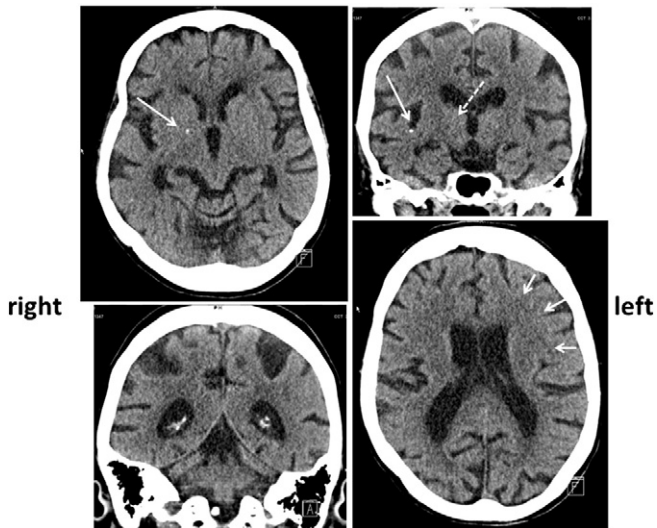


Fig. 1. CT-scan of the brain showing diffuse atrophy (upper left, lower left), slight demyelination periventricularly (arrows, lower right), small lacunas in the basal ganglia (dashed arrow, upper right), and small calcifications of the basal ganglia and the temporal lobe on the right side (arrows, upper left and upper right).

(MSA), progressive supranuclear palsy (PSP), cortico-basal degeneration (CBD), or Lewy-body dementia (LBD), and she had no chorea. It is, however, possible that the presented patient had Alzheimer's disease (SDAT). In the light of the severe morphological cerebral alterations, however, SDAT is not the most probable differential diagnosis in our patient. Diabetes could be responsible for the cognitive decline as well but the degree of cognitive decline was disproportionate to the fasting blood glucose values and the HbA1c values. It is also conceivable that the cerebral alterations were due to a mitochondrial disorder (MID) in addition to the X-ALD carrier status. Arguments for a MID are short stature, hypothyroidism, osteoporosis, anemia, kidney cyst, basal ganglia calcifications, and diabetes. However, further diagnostic work-up into this direction was refused by her legal agent so far. Why dementia did not manifest earlier than at age of 77 years remains speculative, but could be associated with the decreasing VLCFA serum levels in aging X-ALD female carriers (Stradomska and Tylki-Szymańska, 2001) although 20% of the female carriers have normal VLCFA levels (Steinberg and Moser, 1999).

This case shows that manifesting X-ALD carriers may develop progressive severe dementia, severe paraspasticity, and sphincter dysfunction. X-ALD carriers need to be distinguished from multiple sclerosis since they may mimic multiple sclerosis, particularly familial multiple sclerosis. Female X-ALD carriership can be a differential diagnosis of dementia.

References

- Bezman, L., et al., 2001. Adrenoleukodystrophy: incidence, new mutation rate, and results of extended family screening. *Ann. Neurol.* 49, 512–517.
- Boehm, C.D., Cutting, G.R., Lachtermacher, M.B., Moser, H.W., Chong, S.S., 1999. Accurate DNA-based diagnostic and carrier testing for X-linked adrenoleukodystrophy. *Mol. Genet. Metab.* 66, 128–136.
- Brownstone, E., Voigtländer, T., Baumhackl, U., Finsterer, J., 2013. Epilepsy in adult X-linked adrenoleukodystrophy due to the deletion c.1415-1416delAG in exon 5 of the ABCD1-gene. *Gene* 513, 71–74.
- Inoue, K., et al., 1996. Carrier identification of X-linked adrenoleukodystrophy by measurement of very long chain fatty acids and lignoceric acid oxidation. *Clin. Genet.* 50, 348–352.
- Jangouk, P., Zackowski, K.M., Naidu, S., Raymond, G.V., 2012. Adrenoleukodystrophy in female heterozygotes: underrecognized and undertreated. *Mol. Genet. Metab.* 105, 180–185.
- Krenn, M., Bonelli, R.M., Niederwieser, G., Reisecker, F., Költringer, P., 2001. Adrenoleukodystrophy mimicking multiple sclerosis. *Nervenarzt* 72, 794–797.
- Lesca, G., et al., 2005. X-linked adrenoleukodystrophy in a female proband: clinical presentation, biological diagnosis and family consequences. *Arch. Pediatr.* 12, 1237–1240.
- Matsumuro, K., Kuriyama, M., Yoshida, Y., Okatsu, Y., Osame, M., 1991. Symptomatic adrenoleukodystrophy heterozygote with fluctuated neurological symptoms — a case report. *Rinsho Shinkeigaku* 31, 872–874.
- Moser, H.W., Smith, K.D., Watkins, P.A., Powers, J., Moser, A., 2004. X-linked adrenoleukodystrophy. In: Scriver, C.W., Beaudet, A.L., Sly, W., et al. (Eds.), *Metabolic and Molecular Bases of Inherited Disease*, 8th ed. McGraw Hill, New York.
- Powers, J.M., Moser, H.W., Moser, A.B., Ma, C.K., Elias, S.B., Norum, R.A., 1987. Pathologic findings in adrenoleukodystrophy heterozygotes. *Arch. Pathol. Lab. Med.* 111, 151–153.
- Restuccia, D., et al., 1997. Neurophysiological abnormalities in adrenoleukodystrophy carriers. Evidence of different degrees of central nervous system involvement. *Brain* 120, 1139–1148.
- Salsano, E., et al., 2012. Preferential expression of mutant ABCD1 allele is common in adrenoleukodystrophy female carriers but unrelated to clinical symptoms. *Orphanet. J. Rare. Dis.* 7, 10.
- Schlote, W., et al., 1987. Adrenoleukodystrophy in an adult female. A clinical, morphological, and neurochemical study. *J. Neurol.* 235, 1–9.
- Simpson, R.H., Rodda, J., Reinecke, C.J., 1987. Adrenoleukodystrophy in a mother and son. *J. Neurol. Neurosurg. Psychiatry* 50, 1165–1172.
- Steinberg, S.J., Moser, A.B., Raymond, G.V., 1999. X-Linked Adrenoleukodystrophy. In: Pagon, R.A., Bird, T.D., Dolan, C.R., Stephens, K., Adam, M.P. (Eds.), *GeneReviews™*. University of Washington, Seattle, WA ([Internet]. Mar 26 [updated 2012 Apr 19] 1993-. Available from <http://www.ncbi.nlm.nih.gov/books/NBK1315/>).
- Stradomska, T.J., Tylki-Szymańska, A., 2001. Decreasing serum VLCFA levels in ageing X-ALD female carriers. *J. Inher. Metab. Dis.* 24, 851–857.
- van Geel, B.M., 2000. Carrier state of x-linked adrenoleukodystrophy. *Ned. Tijdschr. Geneesk.* 144, 1764–1768.